

Interactive CardioVascular and Thoracic Surgery

Multiple costal cartilage graft reconstruction for the treatment of a full-length laryngotracheal stenosis after an inhalation burn

József Furák, László Szakács, Attila Nagy and László Rovó

Interact CardioVasc Thorac Surg 2011;13:453-455; originally published online Jul 28, 2011;

DOI: 10.1510/icvts.2011.271502

The online version of this article, along with updated information and services, is located on the World Wide Web at:

<http://icvts.ctsnetjournals.org/cgi/content/full/13/4/453>

Interactive Cardiovascular and Thoracic Surgery is the official journal of the European Association for Cardio-thoracic Surgery (EACTS) and the European Society for Cardiovascular Surgery (ESCVS). Copyright © 2011 by European Association for Cardio-thoracic Surgery. Print ISSN: 1569-9293.

Case report - Thoracic non-oncologic

Multiple costal cartilage graft reconstruction for the treatment of a full-length laryngotracheal stenosis after an inhalation burn

József Furák^{a,*}, László Szakács^b, Attila Nagy^b, László Rovó^b^aDepartment of Surgery, University of Szeged, Szeged, Hungary^bDepartment of Oto-Rhino-Laryngology, Head and Neck Surgery, University of Szeged, Szeged, Hungary

Received 11 March 2011; received in revised form 4 July 2011; accepted 15 July 2011

Abstract

After suffering an inhalation burn, a 22-year-old male was intubated for seven days. Full-length massive scar formation in the upper airway necessitated tracheostomy five months later. After this, the stenosis became complete in the cricoid region, and a long cannula was needed to maintain the severely damaged middle–distal trachea. After unsuccessful laser dilatation, the more stenotic 3 cm distal tracheal segment was resected, but two months later the stenosis recurred. As resection was ineffective, tracheoplasty was performed via a right-sided thoracotomy; the re-stenotized trachea was incised in length and successfully extended with 5 cm long, oval-shaped rib cartilage. Three months later, the complete cricotracheal stenosis was fixed by combined laryngofissure and cricoid laminotomy with two 6 cm×2.5 cm cartilage pieces sutured into the incisions. The middle portion of the trachea was expanded with a similar graft inserted into the anterior wall below the tracheostomy. The fixing T-tube was removed three months later, and the patient had an adequate airway two years after the last procedure. We conclude that multiple cartilage graft reconstruction can be successful even after the development of an extremely long airway stenosis following inhalation burn injury.

© 2011 Published by European Association for Cardio-Thoracic Surgery. All rights reserved.

Keywords: Burn injury; Costal cartilage graft; Laryngotracheal stenosis

1. Introduction

Tracheal resection for a postintubation or post-tracheostomy stenosis is a well-detailed procedure, but the management of a tracheal or laryngotracheal stenosis caused by an inhalation injury remains a challenge [1–3]. A lesion caused by irritant gases accompanied by heat is generally more extensive and more frequently transmural than one after postintubation stenosis or tracheostomy. We report here on successful multiple costal cartilage grafting (CCG) to treat a full-length complete laryngotracheal stenosis that developed after an inhalation injury.

2. Case report

While rescuing neighbors from a burning house, a 22-year-old male suffered severe burns to his airway and was intubated for seven days. Five months later, a slowly increasing stridor necessitated a tracheostomy. The endoscopic and computed tomographic examinations revealed a complete cricotracheal stenosis associated with a posterior glottic stenosis with median fixation of the vocal folds (Fig. 1a) and stenosis (at least 50% in caliber) involving the full length of the

trachea (Fig. 1c). The normal airway mucosa disappeared, and diffuse scar formation could be observed with marked thickening from the sixth cartilage ring up to the bifurcation.

The patency of the airway was maintained with a long tracheal cannula (TRACOE 8.0, 202D, TRACOE Med GMBH, Frankfurt, Germany). The granulation that developed at the end of the cannula required trans-stomal carbon dioxide (5–10 W) endoscopic laser vaporization coupled with topical mitomycin C application six times over the next 15 months. The patient's status was worsened by recurrent *Pseudomonas* bronchopneumonias.

The difficulties encountered in the management of the distal stenosis necessitated tracheal resection through a partial median sternotomy. The stenosis located between the fourth and sixth cartilages above the carina was resected, and the anastomosis was performed with absorbable interrupted sutures (Vicryl 3-0). Because of the subglottic stenosis, a normal-length tracheostomy cannula was permanently used, but two months later stenosis recurred at the resection site, and a long tracheostomy cannula had to be reinserted. The pathology on the resected trachea revealed extended fibrosis with a few cartilage islands. The recurrent *Pseudomonas* bronchopneumonias and the incessant granulation at the cannula tip led to a critical condition. As the severely damaged tracheal structure did not allow successful resection, tracheoplasty was decided on 2.5 years after the injury.

*Corresponding author. Pécsi u., H-6701 Szeged, Poland. Tel.: +36-30-9955 815; fax: +36-62-545 701.

E-mail address: jfurak@gmail.com (J. Furák).

© 2011 Published by European Association for Cardio-Thoracic Surgery

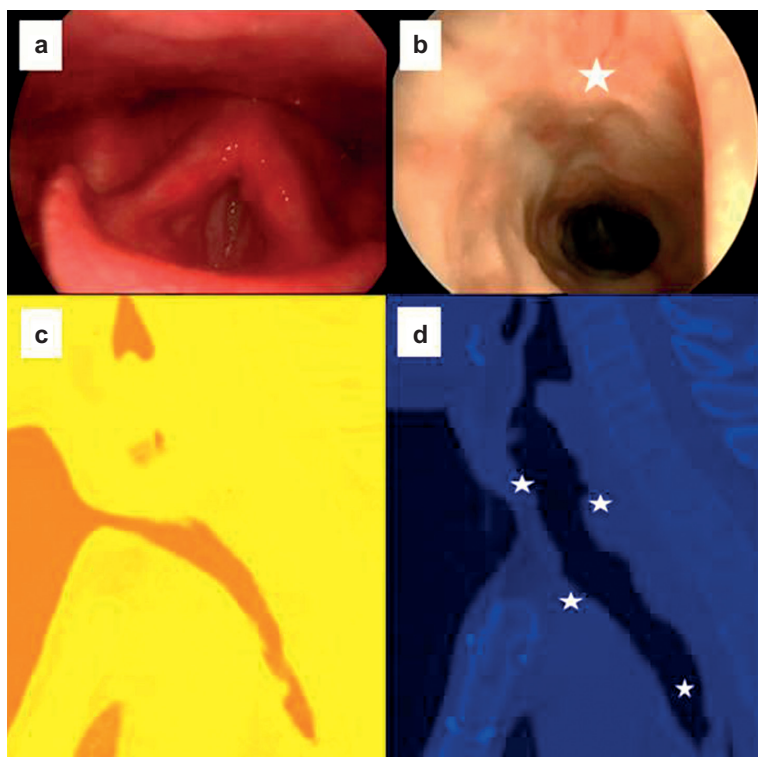


Fig. 1. Pre- and postoperative (two years after tracheoplasty) images. (a, b) Endoscopic pictures. (c, d) Median sagittal computed tomography reconstruction (three-dimensional Slicer software, Brigham and Women's Hospital, Harvard University, Boston, MA, USA). Stars show the site of the grafts.

The distal tracheal re-stenosis was reconstructed through a right-sided thoracotomy (Fig. 2a). The critically narrow site was then found to be 4 cm long, in comparison with 2–3 cm at the first resection. The scarred part of the trachea was opened over a length of 5 cm, and oval-shaped (5 cm×2 cm) rib cartilage (taken from the rib arch) was inserted into the incision and fixed with interrupted absorbable sutures (Vicryl 2-0) to dilate the airway. The tracheoplasty site was covered with an intercostal muscle flap. A long cannula was used as a stent for three months and then replaced by a short one, without re-stenosis.

Following this success, the laryngotracheal part was reconstructed via a collar incision laryngofissure and cricoid laminotomy, and two 6 cm×2–3 cm rib grafts were applied for 'lumen formation' by posterior (Fig. 2b) and anterior (Fig. 2c) dilatation of the complete laryngotracheal stenosis. During the same intervention, the middle tracheal segment was expanded with an anteriorly placed 6×2 cm rib graft after longitudinal median incision of the trachea below the tracheostomy site (Fig. 2d). These grafts were secured by interrupted Vicryl 2.0 sutures. The three partially overlapping grafts provided an adequate airway for the larynx, and upper-middle trachea T-tube stenting was used for three months. The control computed tomography scan and tracheo-endoscopy revealed only slight re-stenosis two years after the last procedure (Fig. 1b,d).

3. Discussion

Because of the special etiology, healing of the tracheal wall is very important for the success of any surgical reconstruction or plastic procedure. The Boston group found

that the inflammatory component tends to subside over a period of three to five years [3]. In view of this long recovery period, Eliachar et al. have recommended the long-term use of a T-shape silicone tube to maintain the airway, instead of immediate laryngotracheal resection or reconstruction [4]. The mean T-stenting duration applied by the Boston group was 28 months. If resection was performed, they recommended T-tube stenting as well [3]. We used a long tracheostomal cannula for almost two years before the resection, and permanently afterwards. Re-stenosis nevertheless developed, as a stable anastomosis could not be created in the severely damaged tracheal tissues by removing only the most stenotized area.

Airway dilatation with a rib cartilage allograft was introduced by Rethi in 1955 [5] and popularized by Cotton [6], mainly for pediatric subglottic stenoses [7, 8]. The Boston group mentioned the same single-graft procedure shortly after the burning injury [3], but in both cases re-stenosis developed. In our patient, the distal tracheal stenosis was managed with success 2.5 years after the injury, and the complete glotto-subglottic and upper tracheal stenosis (practically the full length of the upper airway) was also later reconstructed with a similar technique. Besides the timing of the procedure, the size of the graft(s) should be considered because of the expected partial resorption of free grafts in this condition.

Our case demonstrates that re-stenosis of a burn-injured trachea may occur even two years after a thermal injury. A multilevel CCG procedure to dilate the full-length damaged upper airway was successful 2.5 years after the injury. Well-managed and well-timed multiple tracheoplasty could

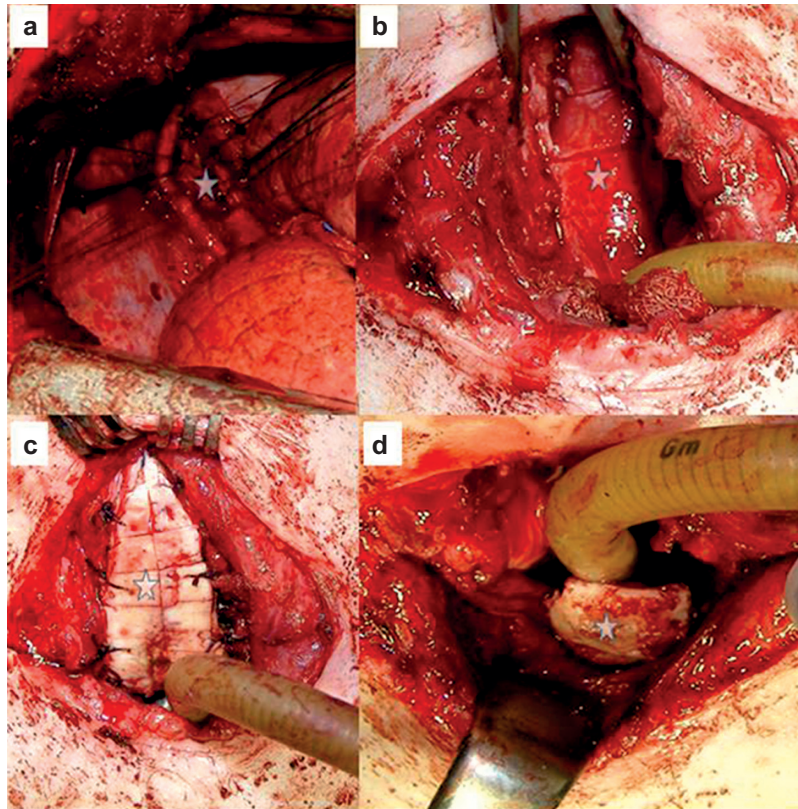


Fig. 2. Intraoperative pictures. Tracheoplasty at the distal trachea (a), posterior larynx (b), anterior larynx (c) and middle trachea (d).

be a reliable alternative to tracheal transplantation or techniques based on stem cell technology in these cases.

References

- [1] Pearson FG, Brito-Filomeno L, Cooper JD. Experience with partial cricoid resection and thyrotracheal anastomosis. *Ann Otol Rhinol Laryngol* 1986;95:582-585.
- [2] Macchiarini P, Verhoye J-Ph, Chapelier A, Fadel E, Dartevielle Ph. Partial cricoidectomy with primary thyrotracheal anastomosis for postintubation subglottic stenosis. *J Thorac Cardiovasc Surg* 2001;121:68-76.
- [3] Gaissert HA, Lofgren RH, Grillo H. Upper airway compromise after inhalation injury. *Ann Surg* 1993;218:672-678.
- [4] Eliachar I, Moscona R, Joachim HZ, Hirschowitz B, Shilo R. The management of laryngotracheal stenosis in burned patients. *Plastic Reconstr Surg* 1981;68:11-16.
- [5] Rethi A. Une nouvelle technique chirurgicale pour le traitement de la fixation bilatérale des cordes vocales. *Laryngol Rhinol Otol (Stuttg)* 1955;34:464-472.
- [6] Cotton R. Management of subglottic stenosis in infancy and childhood: review of a consecutive series of cases managed by surgical reconstruction. *Ann Otol Rhinol Laryngol* 1978;87:649-657.
- [7] George M, Jaquet Y, Ikonomidis C, Monniere PH. Management of severe pediatric subglottic stenosis with glottic involvement. *J Thorac Cardiovasc Surg* 2009;139:411-417.
- [8] Boardman SJ, Albert DM. Single-stage and multistage pediatric laryngotracheal reconstruction. *Otolaryngol Clin N Am* 2008;41:947-958.

Multiple costal cartilage graft reconstruction for the treatment of a full-length laryngotracheal stenosis after an inhalation burn
József Furák, László Szakács, Attila Nagy and László Rovó
Interact CardioVasc Thorac Surg 2011;13:453-455; originally published online Jul 28, 2011;
DOI: 10.1510/icvts.2011.271502

This information is current as of September 22, 2011

**Updated Information
& Services**

including high-resolution figures, can be found at:
<http://icvts.ctsnetjournals.org/cgi/content/full/13/4/453>

Permissions & Licensing

Requests to reproducing this article in parts (figures, tables) or in its entirety should be submitted to: icvts@ejcts.ch

Reprints

For information about ordering reprints, please email:
icvts@ejcts.ch

Interactive CardioVascular and Thoracic Surgery