

Review Article

Smaller amygdala is associated with anxiety in patients with panic disorder

Fumi Hayano, PhD,¹ Motoaki Nakamura, MD, PhD,¹ Takeshi Asami, MD, PhD,^{3,4}
Kumi Uehara, MD,¹ Takeshi Yoshida, MD, PhD,¹ Tomohide Roppongi, MD,¹
Tatsui Otsuka, MD, PhD,¹ Tomio Inoue, MD, PhD² and Yoshio Hirayasu, MD, PhD^{1*}

Departments of ¹Psychiatry, and ²Radiology, Graduate School of Medicine, Yokohama City University, Kanagawa, Japan, Department of Psychiatry, ³Veterans Affairs Boston Healthcare System and ⁴Brigham and Women's Hospital, Harvard Medical School, Boston, USA

Aims: Anxiety a core feature of panic disorder, is linked to function of the amygdala. Volume alterations in the brain of patients with panic disorder have previously been reported, but there has been no report of amygdala volume association with anxiety.

Methods: Volumes of hippocampus and amygdala were manually measured using magnetic resonance imaging obtained from 27 patients with panic disorder and 30 healthy comparison subjects. In addition the amygdala was focused on, applying small volume correction to optimized voxel-based morphometry (VBM). State-Trait Anxiety Inventory and the NEO Personality Inventory Revised were also used to evaluate anxiety.

Results: Amygdala volumes in both hemispheres were significantly smaller in patients with panic disorder compared with control subjects (left: $t = -2.248$, d.f. = 55, $P = 0.029$; right: $t = -2.892$, d.f. = 55, $P = 0.005$). VBM showed that structural

alteration in the panic disorder group occurred on the corticomedial nuclear group within the right amygdala (coordinates [x,y,z (mm)]: [26,-6,-16], Z score = 3.92, family-wise error-corrected $P = 0.002$). The state anxiety was negatively correlated with the left amygdala volume in patients with panic disorder ($r = -0.545$, $P = 0.016$).

Conclusions: These findings suggested that the smaller volume of the amygdala may be associated with anxiety in panic disorder. Of note, the smaller subregion in the amygdala estimated on VBM could correspond to the corticomedial nuclear group including the central nucleus, which may play a crucial role in panic attack.

Key words: amygdala, hippocampus, magnetic resonance imaging, panic disorder, voxel-based morphometry.

PANIC DISORDER (PD) is a complex anxiety disorder characterized by recurrent episodes of sudden and uncontrollable fear (panic attack) and autonomic imbalance such as palpitation, perspiration, trembling, shortness of breath, a sense of suffocation, chest pain or discomfort, nausea or gastrointestinal discomfort, and dizziness.

*Correspondence: Yoshio Hirayasu, MD, PhD, Department of Psychiatry, Graduate School of Medicine, Yokohama City University, 3-9 Fukuura, Kanazawa-ku, Yokohama, Kanagawa 236-0004, Japan. Email: hirayasu@yokohama-cu.ac.jp
Received 23 October 2008; revised 3 February 2009; accepted 8 February 2009.

The amygdala, a major target in the present study, is divided phylogenetically into two groups: the corticomedial nuclear group and basolateral nuclear group.^{1,2} The corticomedial nuclear group includes the cortical nucleus (CO), medial nucleus (ME) and central nucleus (CE). The basolateral nuclear group includes the lateral nucleus (LA), basal nucleus (BA), and accessory basal nucleus (ABA). The corticomedial nuclear group occupies the dorsal medial area in amygdala.³ The CE is located near the tail of the caudate nucleus and putamen, mamillary body, and hippocampal head.⁴

The neurobiological pathway of PD has been considered to act along a circuit mainly involving the

amygdala according to previous animal studies.^{5–7} Viscerosensory information is conveyed to the CE via LA and BA in the amygdala. When the CE recognizes input information as ‘fear’, it activates the autonomic nervous system.⁷ Thus these studies suggest that the CE plays a very important role in PD pathophysiology.

Recently human brain regions including the medial temporal lobe, amygdala, and hippocampus have been linked to anxiety and depression.^{8–10} Regional gray matter (GM) volume reduction in the brain of patients with PD compared with healthy controls has been reported on magnetic resonance imaging (MRI). Manual tracing studies for PD showed smaller GM volumes in right temporal lobe,¹¹ bilateral temporal lobes,¹² and bilateral amygdala.¹³ Previous voxel-based morphometry (VBM) studies for PD demonstrated volume reduction in the left parahippocampal gyrus;¹⁴ volume increase in the midbrain, rostral pons and the left hippocampus with a prefrontal cortex volumes decrease;¹⁵ increased GM volume in the left insula, the left superior temporal gyrus, the midbrain and the pons, and volume reduction in right anterior cingulate cortex.¹⁶ Asami *et al.* previously reported the volume reduction of the right anterior cingulate cortex (ACC) in PD¹⁷ although no relationship was detected between ACC volumes and anxiety.

The basic conception of PD is fear of panic attack and anticipatory anxiety, ‘Panic attack may happen to me’. Fear and anxiety are inseparably connected the function of the amygdala, and the sense of fear is stored in the hippocampus area. The amygdala and hippocampus may play an important role in PD but there have been few MRI structural studies, or studies on the association of structure with function, in those regions.

The combination of region of interest (ROI) and optimized VBM was used in the present study. It has been suggested that the manually traced ROI is superior in anatomical accuracy to the atlas-based ROI in optimized VBM, although it may be potentially influenced by rater bias. In contrast, optimized VBM may be unbiased, and reproducible. Therefore, it has been suggested that the manually traced ROI and optimized VBM provide different aspects of information and should thus be used in tandem.¹⁸

The aim of the present study was to investigate structural alterations in the hippocampus and amygdala of PD patients compared with healthy comparison (HC) subjects. Subsequent VBM with

small volume correction was applied to investigate which subregion in the medial temporal region might be more affected in PD patients. Furthermore, we investigated whether any structural alteration in the medial temporal region may be associated with anxiety in the PD population. As far as we know, this is the first paper to report a structure–function association between amygdala volume and anxiety in PD.

METHOD

Subjects

Thirty patients with PD and 30 HC subjects participated in the present study. The PD patients were recruited from inpatients and outpatients at Yokohama City University Hospital between March 2005 and August 2007. HC subjects, who were mostly medical personnel, were recruited from the University Hospital between March 2006 and September 2007. All subjects met the following criteria: age 18–60 years; IQ > 70;¹⁹ right-handedness (handedness > 0 on the Edinburgh Inventory);²⁰ negative history of epileptic seizures, traumatic brain injury with loss of consciousness, and any neurological disorder; and no lifetime history of alcohol or drug dependence. Neither the HC subjects nor their first-degree relatives had Axis I psychiatric disorders.

Diagnosis of PD was determined for each patient according to DSM-IV criteria²¹ through the Structured Clinical Interview for DSM-IV Axis I Disorder (SCID-I) Clinical Version.²² One patient was excluded due to comorbid psychiatric disorder of Axis I, eating disorder (anorexia nervosa), and receiving atypical antipsychotic (risperidone). Two patients refrained from MRI due to fear of a panic attack in the MRI unit. Therefore, the final number of patients was 27 (10 male, 17 female) with a mean age of 38.2 years. The patient group included 11 patients with agoraphobia and three patients with a past history of major depression, illnesses that are often associated with panic disorder. At the time of the MRI, the patients were variously receiving benzodiazepine alone ($n = 4$); selective serotonin re-uptake inhibitor (SSRI) alone ($n = 3$); SSRI and serotonin noradrenalin re-uptake inhibitor (SNRI; $n = 1$); benzodiazepine and SSRI ($n = 12$); benzodiazepine and SNRI ($n = 2$); benzodiazepine and tricyclic antidepressant ($n = 2$); or benzodiazepine, SSRI and tetracyclic antidepressant ($n = 1$). Clinical symptoms were evaluated using the Panic Disorder Severity Scale (PDSS).²³

Thirty matched HC subjects (35.3 years; nine male, 21 female; all right-handed) were assessed with SCID for non-patients (SCID-NP)²¹ and the Mini-International Neuropsychiatric Interview (M.I.N.I.)^{56,57}.

The subjects' own and parental socioeconomic status (SES) were evaluated for all subjects.²⁴ The global assessment of functioning (GAF) scale (range, 1–100) of Axis V in SCID was used to evaluate general functioning level; higher values reflected better overall functioning. This study was approved by the Medical Research Ethics Committee of Yokohama City University. Written informed consent was obtained from all subjects before study participation.

Magnetic resonance imaging

Procedure

MRI was done with a 1.5-T Magnetom Symphony (Siemens Medical System, Erlangen, Germany) at Yokohama City University Hospital. Turbo fast low-angle shot sequence yielded a sagittal series of 128 contiguous 1.5-mm images (echo time [TE], 3.93 ms; repetition time [TR], 1960 ms; inversion time [TI], 1100 ms; flip angle, 15°; field of view [FOV], 24 cm; matrix, 256 × 256 × 128; voxel dimensions, 0.9375 × 0.9375 × 1.5 mm). Next, a spin-echo yielded 60 contiguous axial turbo spin-echo slices throughout the brain (TE, 93 ms; TR, 3400 ms; FOV, 24 cm; matrix, 256 × 256 × 128; voxel dimensions, 0.9375 × 0.9375 × 3.0 mm).

Regions of interest

The ROI were the amygdala and hippocampus, which were delineated manually using a medical image analysis software package (3D slicer, <http://www.slicer.org>).

The anterior boundary of the amygdala was defined as the most anterior slice where the temporal stem clearly appeared on the coronal section.^{25,26} The amygdala was separated from the hippocampal head as a marker of the alveus, the semi-lunar sulcus, or the uncus recess of the inferior horn of the lateral ventricle.²⁷ The hippocampus contains the Ammon's horn, dentate gyrus, fimbria, and subiculum. The posterior end slice of the hippocampal tail was defined as the slice in which the crus of the fornix was the longest on the coronal section.²⁸

MRI volumetry

Volumetry in each hemisphere for the 57 subjects was performed by F.H., blinded to diagnosis. Interrater reliability for all ROI was examined in five randomly assigned cases by two raters (F.H., K.U.), who were blind to diagnosis. Intra-class correlation coefficients (Cronbach's alpha) were 0.95 and 0.94 for left and right amygdala, and 0.93 and 0.93 for left and right hippocampus, and 0.99 for intracranial content (ICC). Intrarater reliability was also evaluated in 10 randomly assigned cases by F.H. with Cronbach's alpha of 0.95 and 0.96 for left and right amygdala, and 0.99 and 0.99 for left and right hippocampus, and 0.99 for ICC.

Statistical analysis

Statistical analysis was performed using SPSS version 11.0J for Windows (SPSS, Chicago, IL, USA). Volume of the ICC was used to control for head size differences; relative volume was computed for specific ROI: relative volume = (ROI volume/ICC volume) × 100. Tests for group difference in ICC were conducted using *t*-test.

The primary analysis of ROI was a three-way analysis of variance (ANOVA) for relative volumes with a between-subjects factor of diagnostic group and two within-subjects factors of hemisphere (left, right) and region (amygdala, hippocampus). As a follow-up test, we performed a two-way ANOVA (between-subject factor: group; within-subject factor: hemisphere) for each region. To evaluate the likely importance of these findings, we also computed effect size using Cohen's *d*.²⁹

VBM protocol

Differences in localized ROI were assessed using optimized VBM,⁶ an extension of the originally introduced standard VBM technique.^{30,31} The automated image processing was done using the Statistical Parametric Mapping (SPM)2 software (Wellcome Department of Cognitive Neurology, London, UK), running MATLAB (MathWorks, Natick, MA, USA). First, an optimized study-specific template set consisting of a T1 image and a priori GM, white matter (WM), and cerebrospinal fluid (CSF) probability maps, was created for the VBM analysis. This template set was constructed from brain scans taken from all subjects. All scans were first spatially normalized to the Inter-

national Consortium for Brain Mapping template (Montreal Neurological Institute, Montreal, Canada), which approximates Talairach space. The normalized images of all participants were averaged and smoothed with an 8-mm full-width at half-maximum (FWHM) Gaussian kernel and then used as a new template with a reduced scanner- and population-specific bias. In the second normalization step we locally deformed each image of the entire group to the new study-specific template using a non-linear spatial transformation. The normalized images, using a modified-mixture model cluster analysis, were corrected for non-uniformities in signal intensity and then segmented into GM, WM, CSF and background, using the study-specific customized prior probability maps. To remove unconnected non-brain voxels (e.g. rims between the brain surface and meninges), a series of morphological erosions and dilations were applied to the segmented images. To modulate the intensity, voxel values of the segmented images were multiplied by the measure of warped and unwarped structures derived from the non-linear step of the spatial normalization (Jacobian determinant). This step converts relative regional GM density to absolute GM density, expressed as the amount of GM per unit volume of brain tissue prior to spatial normalization. Finally, the modulated images were smoothed using an 8-mm FWHM Gaussian kernel.³²

The group comparisons were analyzed using the smoothed GM images with SPM2. The difference in GM volume between PD patients and HC subjects was assessed on ANCOVA. The ICC was included as a covariate in the model. Once the group difference was found for the amygdala, an ROI analysis was performed with small volume correction (SVC) to investigate which part could be most affected within the amygdala ROI using WFU_Pickatlas software.³³ The result of this analysis was threshold at family-wise false-positive error (FWE)-corrected P ($P < 0.05$).

Clinical and psychological evaluation

Correlation analysis was carried out to examine the impact of age, SES, GAF score, years of schooling, Wechsler Adult Intelligence Scale–Revised IQ score, years of medication, duration of illness, severity of symptoms (PDSS) and dosage of medication³⁴ on each region volumes. Correlation showed that each volume obtained from manual tracing and optimized VBM were unaffected by these factors.

As part of the psychological evaluation, we used the State–Trait Anxiety Inventory (STAI),³⁵ and the NEO Personality Inventory–Revised (NEO-PI-R).³⁶

The STAI consists of the Trait form (STAI-T) and the State form (STAI-S). STAI-T and STAI-S are 20-item self-report scales that measures participants' degree of trait anxiety and state anxiety, respectively. Each item of trait and state anxiety is rated on a 1–4 scale of severity, with total scores ranging from 20 to 80.

The NEO-PI-R is a 240-item self-report scale that covers each of the big five adult personality traits: Neuroticism (NEO-N), Extraversion (NEO-E), Openness (NEO-O), Agreeableness (NEO-A), and Conscientiousness (NEO-C). Items consist of statements that respondents rate on a 5-point scale ranging from 'strongly disagree' to 'strong agree'.

Psychological evaluations were obtained for 19 out of 27 PD patients (M : F = 8:11) and 28 out of 30 HC subjects (M : F = 9:19). Differences in psychological evaluations between the two groups were tested using independent sample t -tests.

The relationship between anatomical variables of manual tracing volumes and psychiatric evaluation were examined using Pearson's correlation. For the correlation analysis, we used a Bonferroni correction for the P level for two variables ($P < 0.025$: $0.05/2$) in STAI and for five variables ($P < 0.01$: $0.05/5$) in NEO-PI-R. In addition, the correlation between the amygdala volumes in VBM and psychiatric evaluations was evaluated using two linear contrasts (positive or negative correlation).

RESULTS

Table 1 lists demographic and clinical characteristics of the two study groups. The two groups did not differ significantly in age, gender, handedness, subject's own and parental SES, or IQ score. GAF scores, however, were significantly lower in PD patients than in HC subjects ($t = -8.67$, d.f. = 55, $P < 0.001$). Also, education (years of schooling) was significantly shorter in PD patients than in HC subjects ($t = -2.48$, d.f. = 55, $P = 0.02$). STAI-T and STAI-S scores were significantly higher in PD patients than in HC subjects (STAI-T: $t = 4.54$, d.f. = 45, $P = 0.00004$; STAI-S: $t = 4.26$, d.f. = 45, $P = 0.0001$). Neuroticism score on the NEO-PI-R was also significantly different ($t = 3.27$, d.f. = 45, $P = 0.002$).

Table 1. Subject details

Variable	Panic disorder patients (<i>n</i> = 27)		Healthy comparison subjects (<i>n</i> = 30)		<i>t</i> -test	
	Mean	SD	Mean	SD	<i>t</i> (d.f. = 55)	<i>P</i>
Age (years) [†]	38.2	9.9	35.3	10.5	1.04	0.30
Gender(male/female)	10/17		9/21			
Handedness [‡]	0.97	0.11	0.96	0.11	0.22	0.82
Socioeconomic status [§]						
Subject	2.4	0.9	2.0	0.9	1.78	0.08
Parents	2.4	0.8	2.0	0.6	1.85	0.07
GAF score	67.5	10.6	89.0	6.1	8.67	<0.001
Education(years)	14.0	2.6	15.7	2.6	2.48	0.02*
WAIS-R IQ score [¶]	105.1	13.4	110.1	14.2	1.20	0.23
Age first medicated (years)	33.1	10.0				
Duration of illness (years)	5.4	6.4				
PDSS	8.8	4.8				

**P* < 0.05.

[†]Age ranges for the two groups were 19–57 years and 22–57 years, respectively.

[‡]Handedness was evaluated using the Edinburgh inventory and right-handedness is above zero. Their ranges were 0.5–1.0 and 0.4–1.0, respectively.

[§]Socioeconomic status, assessed using the Hollingshead scale. Higher scores indicate lower status.

[¶]The IQ ranges for the two groups were 74–133 and 81–142, respectively.

GAF, Global Assessment of Functioning; PDSS, Panic Disorder Severity Scale; WAIS-R, Wechsler Adult Intelligence Scale–Revised.

ROI volume

Three-way ANOVA indicated a significant group × hemisphere interaction ($F = 7.957$, d.f. = 1, 55, $P = 0.007$) without main effect of group ($F = 0.115$, d.f. = 1, 55, $P = 0.736$). The two-way ANOVA in amygdala volume showed no significant group × hemisphere interaction ($F = 0.184$, d.f. = 1, 55, $P = 0.669$) and a significant main effect of group ($F = 9.110$, d.f. = 1, 55, $P = 0.004$). The two-way ANOVA in hippocampus volume indicated a significant group × hemisphere interaction ($F = 10.609$, d.f. = 1, 55, $P = 0.002$) without main effect of group ($F = 0.335$, d.f. = 1, 55, $P = 0.565$). Post-hoc *t*-tests indicated that right amygdala volume was significantly different ($t = -2.892$, d.f. = 55, $P = 0.005$) and left amygdala volume also was significantly different ($t = -2.248$, d.f. = 55, $P = 0.029$). *t*-Tests were performed in each hemisphere because there was a group × hemisphere interaction in the hippocampus. The hippocampal volumes, however, did not indicate a significant group difference (right: $t = -0.244$, d.f. = 55, $P = 0.808$; left: $t = 1.467$, d.f. = 55, $P = 0.148$). The effect sizes of Cohen's *d* were medium–

large for amygdala (left, 0.67; right, 0.70) but small–medium for hippocampus (left, 0.39; right, 0.04). These results suggest that the volumes of the bilateral amygdala but not hippocampus were decreased in the PD patients compared with the HC subjects (Fig. 1).

VBM volume

Whole brain analysis of optimized VBM showed that PD patients had significant GM volume reductions in multiple sites including right amygdala.³⁷ To investigate which subregion was more affected within the amygdala, an ROI analysis was performed using small volume correction with threshold at FWE-corrected *P* ($P < 0.05$). A significant volume reduction was seen within the right amygdala (coordinate [x,y,z (mm)]: [26,-6,-16], *Z* score = 3.92, FWE-corrected $P = 0.002$; Fig. 2), which could correspond to the corticomedial nuclear group.

Correlation with volume

We computed Pearson's correlation between manually traced volumes of the bilateral amygdala and

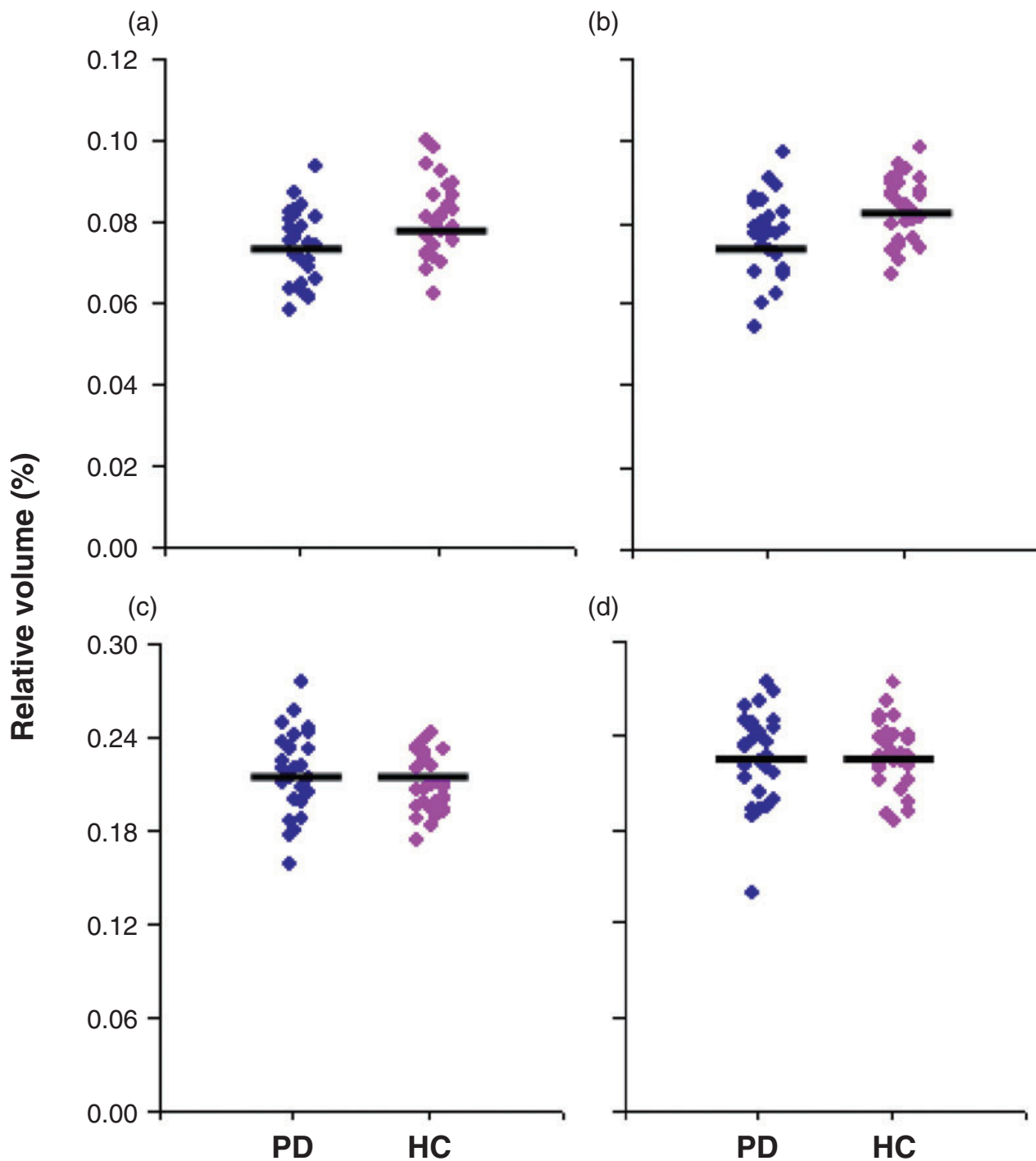


Figure 1. Relative volumes of the amygdala and hippocampus in panic disorder (PD) patients (blue; $n = 27$) and healthy comparison (HC) subjects (pink, $n = 30$). Horizontal bar, mean normalized volumes (absolute amygdalar and hippocampal volume/intracranial content volume) $\times 100$ in (a) left and (b) right amygdala and (c) left and (d) right hippocampal volume. PD patients had smaller amygdala (left, $P = 0.029$; right, $P = 0.005$), compared with HC subjects. There were no group difference for bilateral hippocampus (left, $P = 0.148$; right, $P = 0.806$).

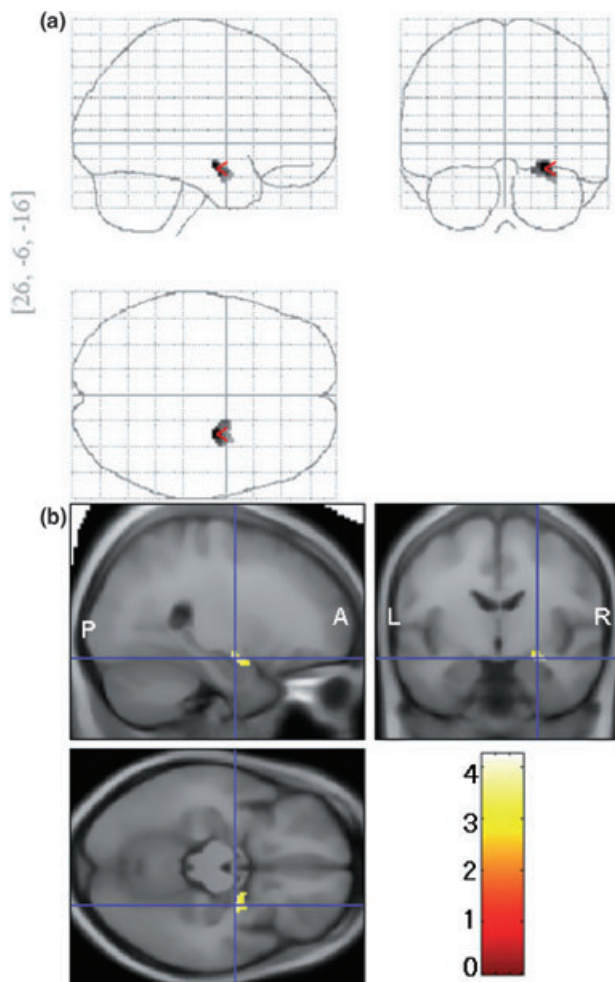


Figure 2. Voxels with a significant decrease in region of amygdala area among panic disorder (PD) patients compared with healthy control (HC) subjects. (a) statistical parametric map showing significantly smaller subregion within the amygdala. (b) The same statistical parametric map overlaid on a structural volume.

hippocampus and psychological evaluation. There was a significant negative correlation between the volume of the left amygdala and STAI-S score for PD patients ($r = -0.545$, $P = 0.016$). Right amygdala volume was associated with neuroticism scores of NEO-PI-R for PD patients ($r = -0.483$, $P = 0.036$; Fig. 3), although it was a trend-level difference after Bonferroni correction. There was no significant correlation between the volume of the left amygdala and STAI-S score in HC subjects ($r = 0.072$, $P = 0.715$), or between the volume of the right amygdala and neuroticism score of NEO-PI-R for HC subjects ($r = 0.017$, $P = 0.931$).

In addition, we examined small-volume corrections for the bilateral amygdala using SPM2. We did not find a correlation between the bilateral amygdala volumes and STAI score or NEO-PI-R score for PD patients and HC subjects.

DISCUSSION

Our previous study found volume reduction of the amygdala when we estimated regional GM volume using optimized VBM for the PD patients.³⁷ The present study showed volume reduction of amygdala in PD patients, confirmed on both manual tracing and optimized VBM with small-volume correction. Furthermore, smaller amygdala was associated with anxiety, suggesting that the amygdala, especially the corticomedial nuclear group, is a crucial area of the neurobiological pathway underlying PD.

The amygdala is a heterogeneous collection of nuclear groups located in the temporal lobe.³⁸ A variety of different functions has been attributed to the amygdaloid complex, including memory, attention, interpretation of emotional significance of sensory stimuli, perception of body movements and generation of emotional aspects of dreams.^{39–41} The amygdala consists of anterior nucleus (AN), LA, BA, CE, ME, CO and ABA. Notably, LA, BA and CE are candidate nuclei related to PD pathophysiology.^{42,43} The LA and BA receive information from the stimulation of various senses.^{44,45} When fear is recognized in BA, the signal is transmitted to CE.⁴⁶ The fiber pathway from CE is connected with fear action and physiological changes. Efferent fibers from CE reach the parabrachial nucleus, which influences respiratory rate,⁴⁷ the hypothalamic lateral nucleus, which induces autonomic arousal and sympathetic discharge,⁴⁸ the hypothalamic paraventricular nucleus, which induces an increase in the release of adrenocorticoids,⁴⁹ the locus ceruleus, which increases norepinephrine release resulting in increases in blood pressure, heart rate, and behavioral fear response,⁵⁰ and the periaqueductal gray region, which is related to defensive behaviors and postural freezing.⁵¹ All these responses develop as autonomic failure in the case of panic attack.

Using VBM we observed significant reduction in the corticomedial nuclear group of the right amygdala in the PD group in comparison with the HC group. Because CE in the corticomedial nuclear group is an area possibly related to autonomic

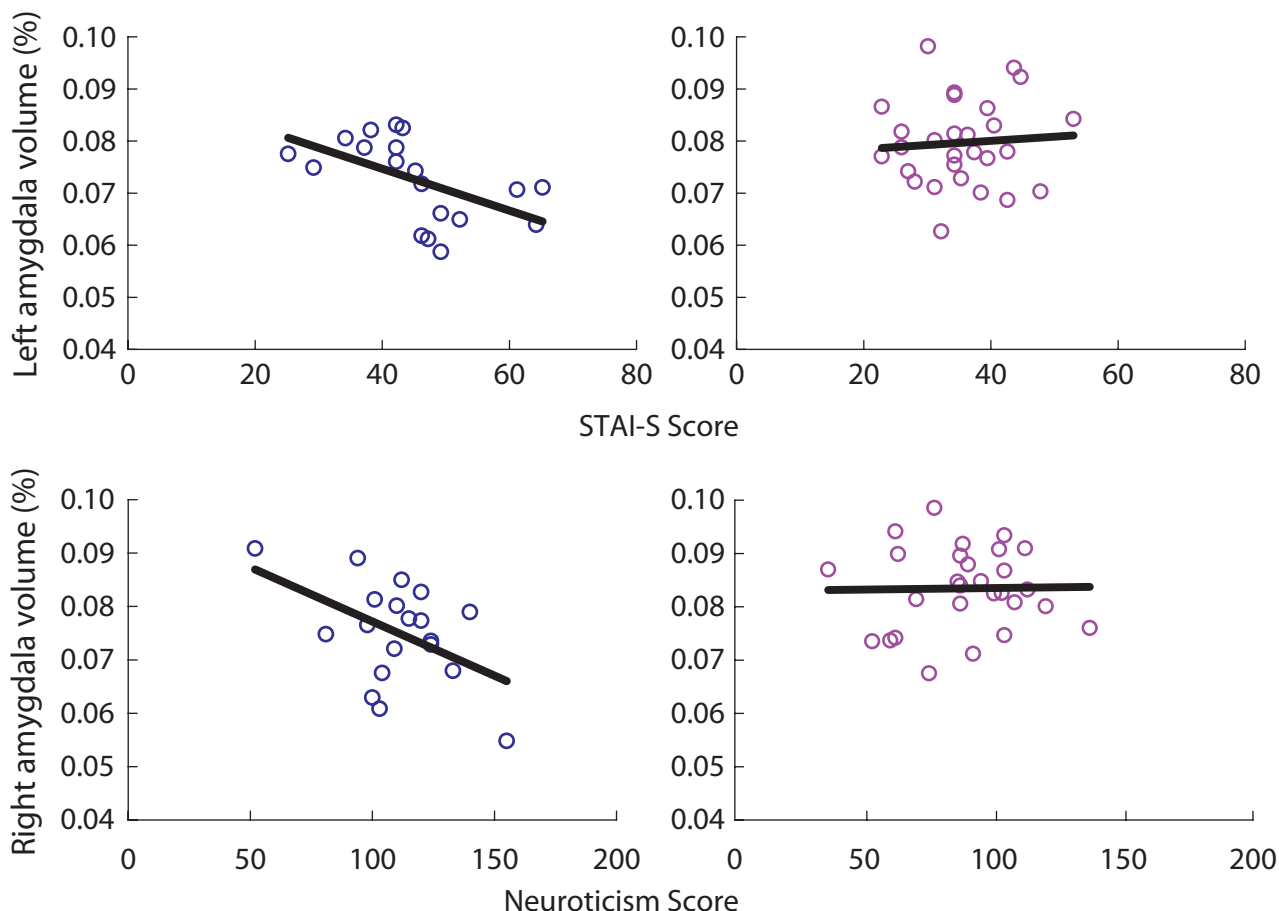


Figure 3. Scatter plots of the correlation between left amygdala volume and STAI-S scores for (a) PD patients ($r = -0.545$, $P = 0.016^*$) and (b) HC subjects ($r = 0.072$, $P = 0.715$) and right amygdala volumes and neuroticism scores of NEO-PI-R for (c) PD patients ($r = -0.483$, $P = 0.036$) and (d) HC subjects ($r = 0.017$, $P = 0.931$). Blue, panic disorder (PD) patients; pink, healthy comparison (HC) subjects. $*P < 0.025$ (0.05/2).

failure during a panic attack, it seems that the volume reduction of this area could affect CE function.

We confirmed no impact of demographic and clinical factors on ROI volume, indicating statistical validity of group comparison. Structure–personality association was examined by calculating correlations between VBM and NEO-PI-R scores. As shown by the Omura *et al.* study, there was a negative correlation between right amygdala volume and neuroticism score of NEO-PI-R.⁵² The present study found similar associations in the PD group: a negative correlation between left amygdala volume and the state anxiety of STAI and a trend-level negative correlation between right amygdala volume and neuroticism of NEO-PI-R. The relationship between amygdala

volume and anxiety was reflected in volume correlations with STAI and NEO, supporting a prior hypothesis of neurobehavioral association between amygdala and anxiety.

In the present study hippocampus volumes did not differ between the study groups. According to a recent report it is suggested that antidepressant treatment may inhibit or reverse the atrophy or damage of hippocampus by upregulation of adult neurogenesis.^{53,54} Furthermore, in another study hippocampus but not amygdala had volume increase on antidepressants.⁵⁵ In the present study the hippocampus volume in the PD group was slightly larger as compared with the HC group (effect size: left, 0.39; right, 0.04), possibly reflecting adult neurogenesis in dentate gyrus induced by antidepressants.

There were methodological limitations in the present study. First, the sample size for subjects in both groups was not large enough. Second, the present study included three subjects with a past history of major depression, therefore this might have affected measurement of the volume. A previous study has reported that there were no significant differences for the volume of whole brain and temporal lobe between PD patients with any current comorbidity and those without comorbidity,¹² but it might have affected measurement of the volume of amygdala and hippocampus. We note here that structural differences between PD patients with and without any comorbidity (current and past), between those with and without agoraphobia should be investigated in future studies with large sample.

In the present study the reduction of amygdala volume in PD was shown on both manual tracing and optimized VBM. Furthermore, the smaller volume of the right amygdala was associated with anxiety. The present results suggest that the smaller volume of the amygdala could reflect a dysfunctional aspect of the region in PD subjects.

ACKNOWLEDGMENTS

This study was supported by a grant from the Ministry of Health, Labor and Welfare (H16: Kokoro 200400762A, H17: Kokoro 200500806A and H18: Kokoro 200632005A, B) of Japan. The authors gratefully acknowledge Adam S. Cohen for critical reading of the manuscript and helpful comments.

REFERENCES

- Crosby EC, Humphrey T. Studies of the vertebrate telencephalon. II. The nuclear pattern of the anterior olfactory nucleus, tuberculum olfactorium and the amygdaloid complex in adult man. *J. Comp. Neurol.* 1941; 47: 309–352.
- Crosby EC, Humphrey T, Lauer EW. *Correlative Anatomy of the Nervous System*. MacMillan, New York, 1962.
- Duvernoy H. *The Human Hippocampus: Functional Anatomy, Vascularization and Serial Sections with MRI*, 2nd edn. Springer, Heidelberg, 1998.
- Ungerstedt U. Stereotaxic mapping of the monoamine pathways in the rat brain. *Acta Physiol. Scand Suppl.* 1971; 367: 1–48.
- Coplan JD, Lydiard RB. Brain circuits in panic disorder. *Biol. Psychiatry* 1998; 44: 1264–1276.
- Good CD, Johnsrude IS, Ashburner J, Henson RN, Friston KJ, Frackowiak RS. A voxel-based morphometric study of ageing in 465 normal adult human brains. *Neuroimage* 2001; 14: 21–36.
- Gorman JM, Kent JM, Sullivan GM, Coplan JD. Neuroanatomical hypothesis of panic disorder, revised. *Am. J. Psychiatry* 2000; 157: 493–505.
- Campbell S, Marriott M, Nahmias C, MacQueen GM. Lower hippocampal volume in patients suffering from depression: A meta-analysis. *Am. J. Psychiatry* 2004; 161: 598–607.
- Geuze E, Vermetten E, Bremner JD. MR-based in vivo hippocampal volumetrics: 2. Findings in neuropsychiatric disorders. *Mol. Psychiatry* 2005; 10: 160–184.
- Videbech P, Ravnkilde B. Hippocampal volume and depression: A meta-analysis of MRI studies. *Am. J. Psychiatry* 2004; 161: 1957–1966.
- Fontaine R, Breton G, Dery R, Fontaine S, Elie R. Temporal lobe abnormalities in panic disorder: An MRI study. *Biol. Psychiatry* 1990; 27: 304–310.
- Vythilingam M, Anderson ER, Goddard A *et al.* Temporal lobe volume in panic disorder: A quantitative magnetic resonance imaging study. *Psychiatry Res.* 2000; 99: 75–82.
- Massana G, Serra-Grabulosa JM, Salgado-Pineda P *et al.* Amygdalar atrophy in panic disorder patients detected by volumetric magnetic resonance imaging. *Neuroimage* 2003; 19: 80–90.
- Massana G, Serra-Grabulosa JM, Salgado-Pineda P *et al.* Parahippocampal gray matter density in panic disorder: A voxel-based morphometric study. *Am. J. Psychiatry* 2003; 160: 566–568.
- Protopopescu X, Pan H, Tuescher O *et al.* Increased brainstem volume in panic disorder: A voxel-based morphometric study. *Neuroreport* 2006; 17: 361–363.
- Uchida RR, Del-Ben CM, Busatto GF *et al.* Regional gray matter abnormalities in panic disorder: A voxel-based morphometry study. *Psychiatry Res.* 2008; 163: 21–29.
- Asami T, Hayano F, Nakamura M *et al.* Anterior cingulate cortex volume reduction in patients with panic disorder. *Psychiatry Clin. Neurosci.* 2008; 62: 322–330.
- Giuliani NR, Calhoun VD, Pearlson GD, Francis A, Buchanan RW. Voxel-based morphometry versus region of interest: A comparison of two methods for analyzing gray matter differences in schizophrenia. *Schizophr. Res.* 2005; 74: 135–147.
- Wechsler D. *Adult Intelligence Scale-Revised*. Harcourt Brace Jovanovich, New York, 1981.
- Oldfield RC. The assessment and analysis of handedness: The Edinburgh inventory. *Neuropsychologia* 1971; 9: 97–113.
- Association AP. *DSM-IV: Diagnostic and Statistical Manual of Mental Disorders*, 4th edn. American Psychiatric Press, Washington, DC, 1994.
- First MB, Spitzer RL, Gibbon M, Williams JBW. *Structured Clinical Interview for DSM-IV Axis I Disorders: Clinical Version (SCID-CV)*. American Psychiatric Press, Washington, DC, 1997.

- 23 Shear MK, Brown TA, Barlow DH *et al.* Multicenter collaborative panic disorder severity scale. *Am. J. Psychiatry* 1997; 154: 1571–1575.
- 24 Hollingshead AB. *Two-Factor Index of Social Position*. Yale University, New Haven, CT, 1965.
- 25 Matsuoka Y, Yamawaki S, Inagaki M, Akechi T, Uchitomi Y. A volumetric study of amygdala in cancer survivors with intrusive recollections. *Biol. Psychiatry* 2003; 54: 736–743.
- 26 Mori E, Ikeda M, Hirono N, Kitagaki H, Imamura T, Shimomura T. Amygdalar volume and emotional memory in Alzheimer's disease. *Am. J. Psychiatry* 1999; 156: 216–222.
- 27 Watson C, Andermann F, Gloor P *et al.* Anatomic basis of amygdaloid and hippocampal volume measurement by magnetic resonance imaging. *Neurology* 1992; 42: 1743–1750.
- 28 Nakano T, Wenner M, Inagaki M *et al.* Relationship between distressing cancer-related recollections and hippocampal volume in cancer survivors. *Am. J. Psychiatry* 2002; 159: 2087–2093.
- 29 Cohen J. *Statistical Power Analysis for the Behavioral Sciences*, 2nd edn. Lawrence Erlbaum Associates, Hillsdale, NJ, 1988.
- 30 Ashburner J, Friston KJ. Voxel-based morphometry: The methods. *Neuroimage* 2000; 11: 805–821.
- 31 Ashburner J, Friston KJ. Why voxel-based morphometry should be used. *Neuroimage* 2001; 14: 1238–1243.
- 32 Salgado-Pineda P, Junque C, Vendrell P *et al.* Decreased cerebral activation during CPT performance: Structural and functional deficits in schizophrenic patients. *Neuroimage* 2004; 21: 840–847.
- 33 Maldjian JA, Laurienti PJ, Kraft RA, Burdette JH. An automated method for neuroanatomic and cytoarchitectonic atlas-based interrogation of fMRI data sets. *Neuroimage* 2003; 19: 1233–1239.
- 34 Inagaki A, Inada T. Dose equivalence of psychotropic drugs. Part X VIII: 2006-version. *Rinsho Seishin Yakuri* 2006; 9: 1443–1447.
- 35 Spielberger C, Gorsuch R, Lushene R. *STAI Manual for the Statetrait Anxiety Inventory*. Consulting Psychologists Press, Palo Alto, 1970.
- 36 Costa PT, McCrae RR. *Professional Manual of the Revised NEO Personality Inventory and NEO Five-Factor Inventory*. Psychological Assessment Resources, Odessa, FL, 1992.
- 37 Asami T, Yamasue H, Hayano F *et al.* Sexually dimorphic gray matter volume reduction in patients with panic disorder. *Psychiatry Res. Neuroimag.* 2008 (in press).
- 38 Pitkanen A, Savander V, LeDoux JE. Organization of intra-amygdaloid circuitries in the rat: An emerging framework for understanding functions of the amygdala. *Trends Neurosci.* 1997; 20: 517–523.
- 39 Morris JS, Frith CD, Perrett DI *et al.* A differential neural response in the human amygdala to fearful and happy facial expressions. *Nature* 1996; 383: 812–815.
- 40 Rauch SL, van der Kolk BA, Fisler RE *et al.* A symptom provocation study of posttraumatic stress disorder using positron emission tomography and script-driven imagery. *Arch. Gen. Psychiatry* 1996; 53: 380–387.
- 41 Scott SK, Young AW, Calder AJ, Hellawell DJ, Aggleton JP, Johnson M. Impaired auditory recognition of fear and anger following bilateral amygdala lesions. *Nature* 1997; 385: 254–257.
- 42 Davis M. The role of the amygdala in fear and anxiety. *Annu. Rev. Neurosci.* 1992; 15: 353–375.
- 43 LeDoux JE, Iwata J, Cicchetti P, Reis DJ. Different projections of the central amygdaloid nucleus mediate autonomic and behavioral correlates of conditioned fear. *J. Neurosci.* 1988; 8: 2517–2529.
- 44 LeDoux JE, Cicchetti P, Xagoraris A, Romanski LM. The lateral amygdaloid nucleus: Sensory interface of the amygdala in fear conditioning. *J. Neurosci.* 1990; 10: 1062–1069.
- 45 Amaral DG, Insausti R. Retrograde transport of D-[3H]-aspartate injected into the monkey amygdaloid complex. *Exp. Brain Res.* 1992; 88: 375–388.
- 46 Amorapanth P, LeDoux JE, Nader K. Different lateral amygdala outputs mediate reactions and actions elicited by a fear-arousing stimulus. *Nat. Neurosci.* 2000; 3: 74–79.
- 47 Takeuchi Y, McLean JH, Hopkins DA. Reciprocal connections between the amygdala and parabrachial nuclei: Ultrastructural demonstration by degeneration and axonal transport of horseradish peroxidase in the cat. *Brain Res.* 1982; 239: 583–588.
- 48 Price JL, Amaral DG. An autoradiographic study of the projections of the central nucleus of the monkey amygdala. *J. Neurosci.* 1981; 1: 1242–1259.
- 49 Dunn JD, Whitener J. Plasma corticosterone responses to electrical stimulation of the amygdaloid complex: Cytoarchitectural specificity. *Neuroendocrinology.* 1986; 42: 211–217.
- 50 Cedarbaum JM, Aghajanian GK. Afferent projections to the rat locus coeruleus as determined by a retrograde tracing technique. *J. Comp. Neurol.* 1978; 178: 1–16.
- 51 De Oca BM, DeCola JP, Maren S, Fanselow MS. Distinct regions of the periaqueductal gray are involved in the acquisition and expression of defensive responses. *J. Neurosci.* 1998; 18: 3426–3432.
- 52 Omura K, Todd Constable R, Canli T. Amygdala gray matter concentration is associated with extraversion and neuroticism. *Neuroreport* 2005; 16: 1905–1908.
- 53 Bachis A, Mallei A, Cruz MI, Wellstein A, Mochetti I. Chronic antidepressant treatments increase basic fibroblast growth factor and fibroblast growth factor-binding protein in neurons. *Neuropharmacology* 2008; 55: 1114–1120.
- 54 Warner-Schmidt JL, Duman RS. Hippocampal neurogenesis: Opposing effects of stress and antidepressant treatment. *Hippocampus* 2006; 16: 239–249.

- 55 Bremner JD, Elzinga B, Schmahl C, Vermetten E. Structural and functional plasticity of the human brain in posttraumatic stress disorder. *Prog. Brain Res.* 2008; **167**: 171–186.
- 56 Otsubo T, Tanaka K, Koda R *et al.* Reliability and validity of Japanese version of the Mini-International Neuropsychiatric Interview. *Psychiatry Clin Neurosci* 2005; **59**: 517–526.
- 57 Sheehan DV, Lecrubier Y, Sheehan KH *et al.* The Mini-International Neuropsychiatric Interview (M.I.N.I.): the development and validation of a structured diagnostic psychiatric interview for DSM-IV and ICD-10. *J Clin Psychiatry* 1998; **59 Suppl 20**: 22–33; quiz 34–57.